



**PRESENTING CLINICAL SIGNS**

History: New grade 2/6 murmur. History of kidney disease and recent UTI.

**DATE**

4/28/22

**ECHOCARDIOGRAPHIC FINDINGS**

2D, M-mode, and Doppler study.

**PERFORMED BY:**

Kelly Vazquez

Left atrial size is normal. The mitral valve appears normal. Left ventricular wall thickness is normal. Left ventricular internal dimensions are normal. Left ventricular systolic function is normal. The aorta and aortic valve are normal. Right atrial and right ventricular dimensions are normal. The tricuspid valve appears normal. The pulmonary artery and pulmonic valve are normal. No pericardial effusion or cardiac masses are seen.

**INTERPRETED BY**

Keith Blass, DVM,  
MS, DACVIM  
(Cardiology)

LA/Ao - 1.27  
IVSd - 4.7 mm  
LVPWd - 4.2 mm  
LVIDd - 13.2 mm  
LVIDs - 6.8 mm  
FS - 48.5%  
LVOT - 0.62 m/s  
RVOT - 0.87 m/s

**PATIENT**

Star Capuano

**ASSESSMENT/RECOMMENDATIONS**

Normal echocardiogram

**SPECIES**

Feline

This examination demonstrates no evidence of structural heart disease. While a definitive reason for Star's murmur was not identified, it's likely that her murmur is functional/innocent in nature, as no flow abnormalities that could result in the development of a pathologic murmur were appreciated in the image set.

**BREED**

DSH

No therapy is recommended based on this exam.

**SEX**

FS

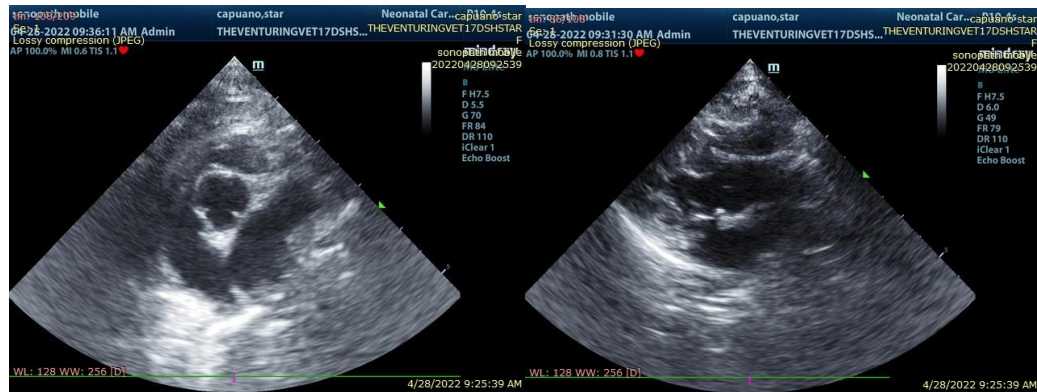
A recheck echocardiogram is recommended if the characteristics of Star's murmur change, or if other new physical exam and/or clinical abnormalities suggestive of cardiac dysfunction develop.

**AGE**

17 y

**WEIGHT**

8 lb



**HOSPITAL NAME**

The Venturing Vet

The information and recommendations provided are based on the images presented by the referring veterinarian. No evaluation can be communicated regarding pathology that was not visible in the image/video clips provided.

**REFERRING VET**

Dr. Herzog

Thank you for this referral. If the clinical or image interpretation does not parallel your findings or if I can be of any further assistance please contact me.



**DATE** Keith Blass, DVM, MS, DACVIM (Cardiology)  
KeithBlass@gmail.com  
4/28/22 631-804-5754

**PERFORMED BY:**

Kelly Vazquez

**INTERPRETED BY**

Keith Blass, DVM,  
MS, DACVIM  
(Cardiology)

**PATIENT**

Star Capuano

**SPECIES**

Feline

**BREED**

DSH

**SEX**

FS

**AGE**

17 y

**WEIGHT**

8 lb

**HOSPITAL NAME**

The Venturing Vet

**REFERRING VET**

Dr. Herzog